Neurite Orientation Dispersion and Density Imaging in People with HIV on Stable Treatment

Phillip Chan[1,2*], Nakul R. Raval[3*], Praveen Honhar[3], Jennifer Chiarella[1], Allison Nelson[1], David Matuskey[1,3,4], Richard Carson[3], Ansel T. Hillmer[3,4], Serena Spudich[1,2]

1. Department of Neurology, Yale University, New Haven, CT, USA, 2. Yale Center for Brain and Mind Health, Yale University, New Haven, CT, USA, 3.Department of Radiology and Biomedical Imaging, Yale University, New Haven, CT, USA, 4. Department of Psychiatry, Yale University, New Haven, CT, USA. *Equal Contribution

Abstract # 00588

BACKGROUND

- The frontostriatothalamic region (FST) is among the most frequently reported regions exhibiting imaging abnormalities in people with HIV (PWH).
- Neurite Orientation Dispersion & Density Imaging (NODDI) is a multi-compartmental diffusion MRI technique that characterizes brain microstructures by quantifying the packing density of axons or dendrites (neurite density index, **NDI**), the orientational coherence of neurites (orientation dispersion index, **ODI**), & the free water fraction (isotropic compartment, **ISO**).
- This preliminary study compares NODDI metrics cross-sectionally between virally suppressed PWH (plasma HIV RNA <20 cps/ml, median duration of treatment: 22 years) & people without HIV (PWOH), & longitudinally in the PWH group over a median duration of 32 months.

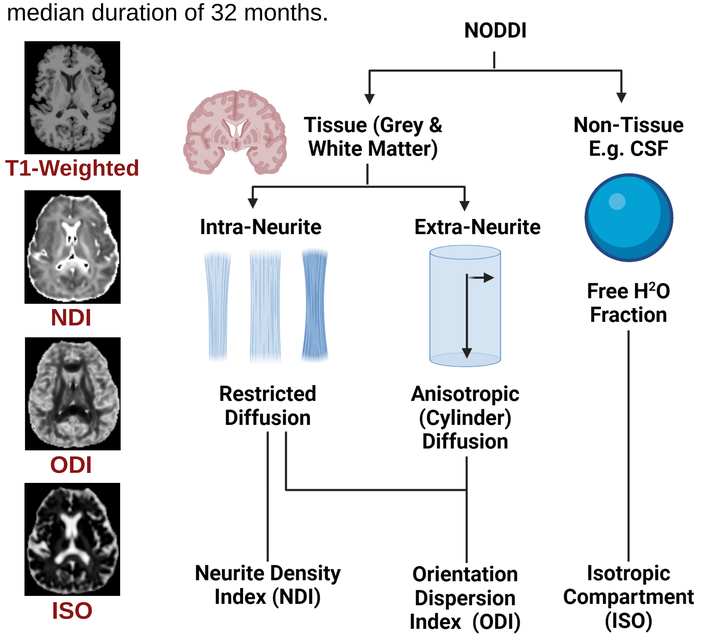

METHODS

- 8 PWH (age: 56 [IQR 53,59], 8/8 male) & 8 PWOH (age: 57 [IQR 53,62], 3/8 male) underwent NODDI in a 3T Siemens Prisma scanner, employing a two-shell NODDI-driven protocol (32,64 direction; b=700,2000 s/mm2; 80 slices; TR/TE=4100/88ms).
- NDI, ODI & ISO were measured in the primary region of interest (ROI), the FST, while NDI was measured in the secondary ROIs, including frontal, parietal, temporal, & occipital lobes, corpus callosum and white matter in FST, after distortion & eddy-current correction & FreeSurfer segmentations.
- Mann-Whitney U & Wilcoxon Signed Rank Test for cross-sectional and longitudinal analyses, respectively.

Over a median duration of 32 months, virally-suppressed PWH exhibited a decrease in neurite density at the frontostriatothalamic region and key cerebral lobes. The findings may represent longitudinal microstructural changes in PWH.

RESULTS

- At the 1st scan, the CD4+ & CD8+ T-cell counts of PWH were 631 [IQR 412,831] & 576 [IQR 442,840] cells/mm^3, with a CD4/CD8 ratio of 0.96 [IQR 0.66,1.36].
- Compared to PWOH, PWH had lower NDI (mean difference Δ=-13.6±6.6%, p=0.001) & ODI (Δ=-12.1±3.7%, p<0.001), but ISO showed no significant difference in the FST region. PWH also had lower cortical NDIs than PWOH (p<0.05), but no significant difference was observed in WM NDIs (**Table**) .
- In the longitudinal analysis, PWH showed a decrease in NDI (Δ=-11.2±9.2%, p=0.02) & ISO (Δ=-17.2±7.6%, p=0.007) but statistically unchanged ODI (Δ=1.5±7.8%, p=0.547) in the FST region. NDIs decreased in all cortical ROIs and WM of FST p<0.05).

Table: Neurite Density Index (NDI) by Region of Interest and Type of Analysis

Regions	Cross-sectional Analysis (PWH vs. PWOH)			Longitudinal Analysis (PWH: 1st vs. 2nd scan)		
	% Difference (SD)	p value	Cohen's d	% Difference (SD)	p value	Cohen's d
Primary Region of Interest						
Frontostriatothalamic (GM)	-13.6 (6.6)	0.001	-2.07	-11.2 (9.2)	0.023	-1.22
Secondary Regions of Interest						
Frontal Lobe (GM)	-15.6 (7.1)	0.001	-2.20	-14.4 (13.4)	0.039	-1.08
Occipital Lobe (GM)	-8.9 (6.8)	0.038	-1.30	-13.0 (12.9)	0.039	-1.01
Parietal Lobe (GM)	-15.3 (8.1)	0.007	-1.89	-16.6 (8.6)	0.008	-1.94
Temporal Lobe (GM)	-9.7 (7.6)	0.007	-1.28	-6.2 (5.4)	0.02	-1.15
Corpus Callosum (WM)	2.8 (8.9)	0.878	0.31	0.2 (11.6)	1	0.01
FST (WM only)	-4.3 (4.9)	0.114	-0.87	-4.1 (2.9)	0.007	-1.39

Mann-Whitney U Test for cross-sectional evaluations; Wilcoxon Signed Rank Test for longitudinal changes.
All p-values are uncorrected for multiple-comparison.
Abbreviations: PWH: People with HIV; PWOH: People Without HIV; SD: standard deviation

Cross-sectional Analysis (PWH vs. PWOH)

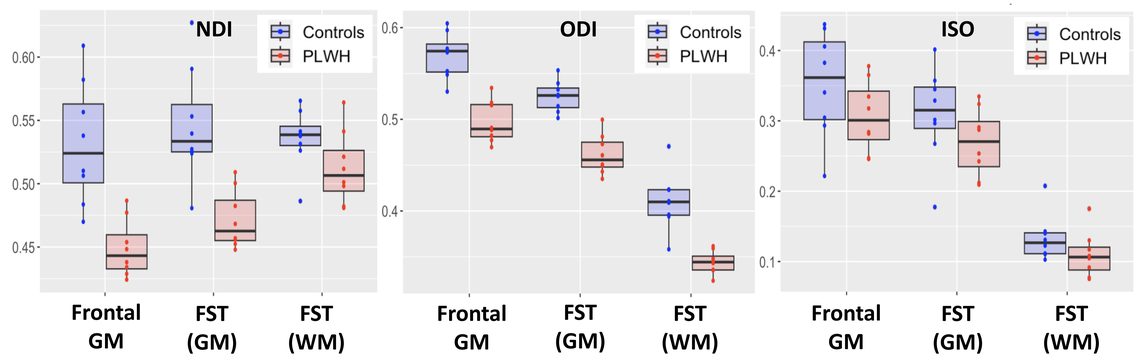

Longitudinal Comparison of NDI in PWH by ROI

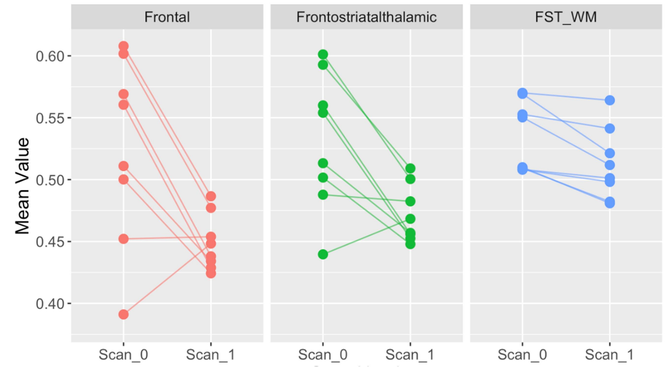

SUMMARY OF FINDINGS

- Virally-suppressed PWH demonstrated lower NDI & ODI at both FST & key lobar regions when compared to PWoH cross-sectionally, suggesting the possible presence of microstructural differences between the two groups.
- Over a median duration of 32 months, despite the maintenance of plasma viral suppression, PWH exhibited a further decrease in NDI in both primary & most secondary ROIs.

TECHNICAL CONSIDERATION

- More recent analyses suggest that the settings in the scanner protocol may contribute to a differential tendency in better capturing white matter (WM) versus gray matter (GM) in NODDI.

CONCLUSIONS & NEXT STEPS

- The longitudinal decline of NDI in PWH may indicate ongoing changes at the axonal/dendritic level.
- NODDI may help understand longitudinal microstructural brain changes in PWH on stable ART.
- Inclusion of cognitive testing, multi-modal neuroimaging, & longitudinal PWOH controls will help validate and understand the observed NODDI changes.

ACKNOWLEDGMENTS

We would like to express our gratitude to the study participants and colleagues at the Yale Magnetic Resonance Research Center (MRRC) who dedicated a significant amount of their time to this study. The research received support from grants provided by the National Institute of Mental Health (NIMH), focusing on neurological and cognitive outcomes (Spudich, R21 MH118023 & R01 MH125396). The work was also made possible by support from AbbVie (Matuskey) and funding from NINDS (Matuskey, R01 NS124819)