0645

TISSUE-RESIDENT T CELL RESPONSES IN HIV+ PATIENTS WITH HPV-DRIVEN ANAL DYSPLASIA

Rehana V Hewavisenti[1], Zong-Hong Zhang[1,2], Cecilia Chang[3,4], Tony Wang[3,4], Deborah Cromer[1], Priyanka S Hastak[1], Fengyi Jin[1], Mary Poynten[1], Fabio Luciani[2], Alexander Swarbrick[3,4], Andrew Grulich[1], Anthony D Kelleher[1] and Sarah C Sasson[1]

[1] Kirby Institute, University of New South Wales, Sydney, Australia. [2] School of Medical Sciences and Cellular Genomics Future Institute, Sydney, Australia, [3] Garvan Institute of Medical Research, Sydney, Australia. [4] Faculty of Medicine and Health, UNSW, Sydney, Australia

BACKGROUND

Human papillomavirus (HPV)-driven anal cancer

- Men who have sex with men (MSM) living with human immunodeficiency virus (HIV) have up to 150x increased risk of HPV-driven anal cancer.
- 60-70% of anal cancer is attributed to HPV16.
- MSM undergoing anti-retroviral therapy have poor HPV clearance & develop high-grade squamous intraepithelial lesions (**HSILs**; a cancer precursor).

Tissue-resident memory T (T_{RM}) cells

- T_{RM} cells are a specialized subset that resides in tissue permanently & are strategically localized in areas of pathogen entry (Sasson et al, Cell Mol Immunol, 2020)
- Cellular expression of CD103$^+$ and/or CD69$^+$
- Highly express immune checkpoint proteins such as .PD-1 and CTLA-4, making them ideal targets for next generation therapeutics.
- CD103+CD8+ T_{RM} cells as associated with positive patient prognosis in cancers such as melanoma, HPV-driven oropharyngeal cancer, and breast cancer (Edwards et al, (2018), Clin. Cancer Res; Hewavisenti et al (2020), J Immunother Cancer; Savas et al (2018), Nat Med).

In the presence of HIV, the role of T_{RM} cells in controlling HPV-driven anal dysplasia is unknown.

AIMS

- To assess HIV-HPV16 co-infection effect on T_{RM} cell **size, distribution, phenotype** and **function**.
- To identify **differential transcriptional profiles** between HSIL regression versus non-regression (persistent disease and high risk of cancer) in MSM with HIV-HPV co-infection.

Methods

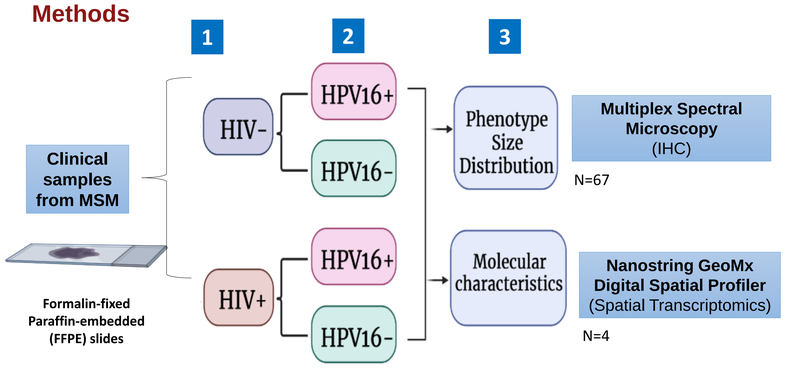

Figure 1. Building a snapshot of the T cell environment in HPV-driven anal dysplasia. FFPE HSILs were sorted by **1)** HIV status, followed by **2)** HPV16 status, to investigate **3)** T cells size, phenotype and function, and HSIL molecular characteristics between regressive and non-regressive HSILs

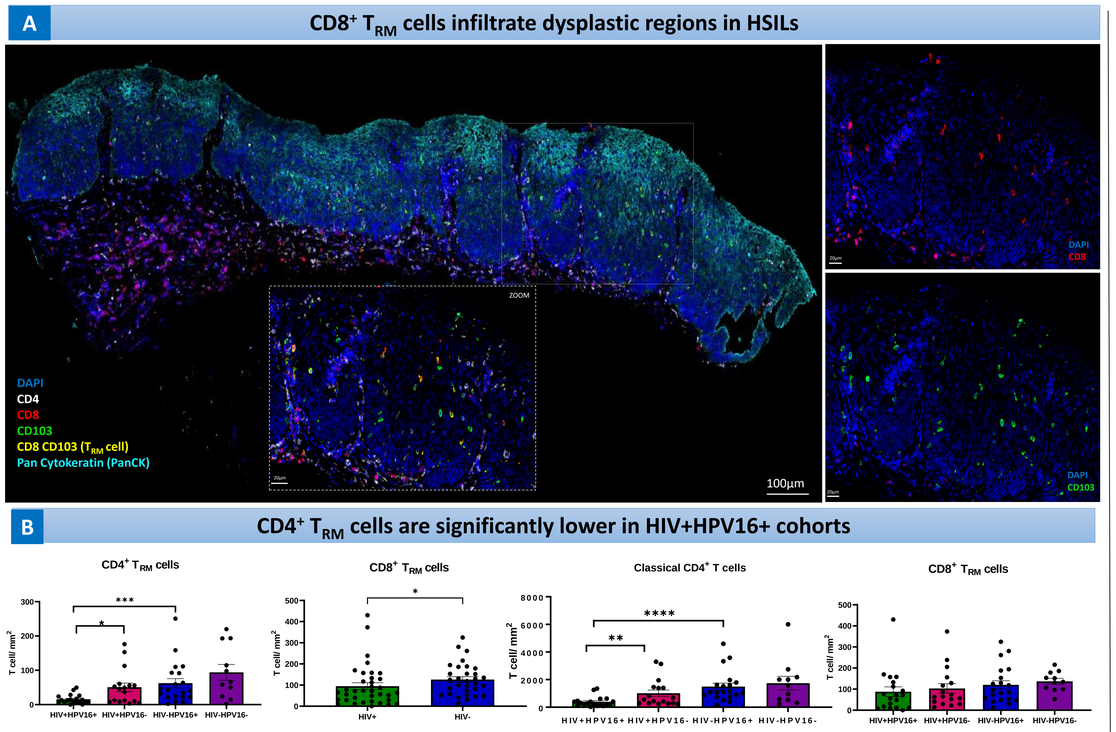

Figure 2: Multiplex spectrometry reveals CD8$^+$ T_{RM} cell infiltration in dysplastic lesions and low CD4$^+$ T cell subsets in HIV+ cohorts. Multiplex image (20x objective) staining of DAPI (blue; cell nucleus), Pan cytokeratin-positive (PanCK+, cyan; dysplastic regions), CD4$^+$ T cells (white), **A)** CD8$^+$ T cells (red) and CD103 (green) which colocalise and represent CD8$^+$ T_{RM} cells (yellow). CD8$^+$ T_{RM} cells visually infiltrate dysplastic lesions more than other T cell subsets (red arrows) **(B)** CD4$^+$ T cells and CD8 T_{RM} cells are lower in HIV+ cohorts. HIV+ (n=36), HIV- (n=31), HIV$^+$HPV16$^+$ (n=19), HIV$^+$ HPV16$^-$ (n=17 ; HIV$^-$HPV16$^+$ (n=20); HIV$^-$HPV16$^-$ (n=11). Mann Whitney T test *p<0.05, **p<0.005,***p<0.0005,****p<0.0001. Classical T cells do not express CD103 and enter from the circulation.

Non-regressive HSILs are transcriptionally different to regressive HSILs in HIV-HPV co-infection



Figure 3. Building a transcriptional snapshot of key signaling pathways in regressive and non-regressive HSILs. The dot plot illustrates signaling pathways evident in dysplastic (PanCK+) regions of regressive (R) and non-regressive HSILs.
Spatial transcriptomics (whole transcriptome atlas analysis) reveals that homeostatic and metal ion regulatory pathways dominate **regressive (R)** lesions versus **non-regressive (NR)** lesions where despite persistent disease, adaptive T cells response, MHC class II antigen processing and presentation, and inflammatory cytokine regulation pathways dominate. NES: Normalized enrichment score. The larger the circle, the more significant the expression (smaller P value; P<0.05).

R: Regressive HSIL *HPV cleared by host immune response*

NR: Non-regressive HSIL *Persistent disease and increased risk of anal cancer.*

High CD8$^+$ T cells numbers are associated with high CD4$^+$ T numbers in HIV+ high-grade lesions

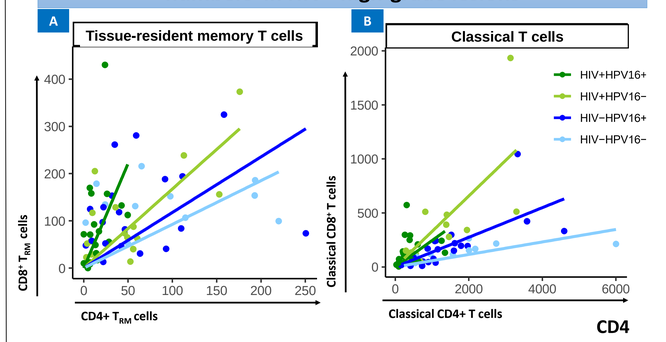

Figure 4: Linear regression analysis of A) tissue-resident T cells and B) classical T cells comparing **HIV+HPV16-** (n=19), **HIV+HPV16-** (n=17); **HIV-HPV16$^+$** (n=20); **HIV-HPV16-** (n=11). Steeper green lines indicate that MSM living with HIV have relatively more CD8$^+$ T cells for the same number of CD4$^+$ T cells.

In HPV16 & HIV co-infection, significantly low numbers of tissue-resident CD4$^+$ and CD8$^+$ T cells are indicative of immune dysfunction

CONCLUSIONS

- HIV infection is comprised of **low CD8$^+$ T_{RMs}** and **CD4$^+$ T_{RMs}**, and **classical CD4$^+$ T cell numbers**.
- CD8$^+$ T_{RM} numbers are associated with **CD4$^+$ T cell lymphopenia in the tissue.**
- Regressive SILs are compromised of homeostatic signals while non-regressive SILs are dominated by MHC regulation and high T cell activity.
- **Low CD4$^+$ T cells** may result in **a lack of essential signals for** CD8+ T_{RM} cell infiltration and cytotoxicity in HPV-HIV co-infection leaving MSM at increased risk of cancer development.

The authors acknowledge the facilities and technical support provided by Microscopy Australia within the Mark Wainwright Analytical Centre (MWAC) at UNSW Sydney and NanoString. Funding support from NIH R21 & NHMRC. Methods graphic: Created with BioRender