602

Hepatocellular carcinoma screening among persons living with HIV and hepatitis B in Zambia

Riebensahm C[1,2], Muula G[3], Chitundu H[4], Hamusonde K[1], Chihota B[2,3,5], Ramírez Mena A[1,2], Sinkala E[4], Sunkutu V[4], Maurer M H[6], Berzigotti A[7,8], Egger M[5,9,10], Bolton-Moore C[4,10], Vinikoor M[3,4,10], Wandeler G[1,5], for IeDEA-southern Africa

[1] Department of Infectious Diseases, Bern University Hospital, University of Bern, Switzerland, [2]Graduate School of Health Sciences, [3]Centre of Infectious Diseases Research in Zambia, Lusaka, Zambia, [4]University Teaching Hospital, Lusaka, Zambia, [5]Institute of Social and Preventive Medicine, University of Bern, Switzerland, [6]Department of Radiology, Inselspital, Bern University Hospital, University of Bern, Bern, Switzerland, [7]Department for Visceral Surgery and Medicine, Inselspital, Bern University Hospital, University of Bern, Bern, Switzerland, [8]Hepatology, Department of BioMedical Research, University of Bern, Bern, Switzerland, [9]Centre for Infectious Diseases Research, University of Cape Town, Cape Town, Republic of South Africa, [10]Department of Medicine, University of Alabama, Birmingham, AL, USA

BACKGROUND

- Chronic hepatitis B virus (HBV) infection is the main cause of hepatocellular carcinoma (HCC) in Sub-Saharan Africa (SSA)
- 6-monthly abdominal ultrasound (AUS) screening is recommended for adults of African origin living with chronic HBV, but few screening programs exist in SSA
- We evaluated the uptake and outcomes of an HCC screening program in a cohort of people living with HIV and HBV on tenofovir-containing antiretroviral therapy in Lusaka, Zambia

METHODS

- We performed AUS imaging every 6 months and collected data using a standardized case-report form
- When a liver lesion >1 cm was documented on AUS, a confirmation four-phase Computer Tomography (4CT) scan was performed
- LI-RADS Version 2017 was used to standardize interpretation and reporting for diagnostic imaging[1]
- All patients had yearly liver stiffness measurements (Fibroscan 402®), HBV viral load, HBV serology, and alcohol consumption assessments using AUDIT-C

Table 1. Patient characteristics at ART start

Characteristics	**N= 281**
Median age, years (IQR)	34 (27-38)
Female sex (%)	115 (40.9)
WHO clinical stage 3 or 4 (%)	98 (36.3)
Median CD4+ count, cells/ul (IQR)	233 (93-338)
HBeAg seropositive, n (%)	94 (40.3)
HBV DNA>2,000, IU/mL (%)	132 (55.5)
Elevated ALT, U/L (%)	133 (54.7)
Hazardous alcohol consumption (%)	123 (46.2)
BMI > 25.5, n (%)	36 (12.8)
LSM > 7.0 , kPa (%)	39 (15.4)
LSM > 9.4 , kPa (%)	25 (9.8)

ART, antiretroviral treatment; IQR, Interquartile range; WHO, World Health Organization, HBV, Hepatitis B virus; DNA, Deoxyribonucleic acid; ALT, Alanine aminotransferase; BMI, body mass index; LSM, liver stiffness measurement

- **Comprehensive HCC screening, including 6-monthly abdominal ultrasound and confirmatory four-phase CTscan is feasible in Zambia**
- **Over 1,075 person-years of follow-up, no incident HCC were diagnosed among people living with HIV and HBV on tenofovir-containing ART**

RESULTS

- Of 303 eligible participants, 281 (92.7%) had at least one AUS measurement
- Using transient elastography, 39 (15.4%) had significant liver fibrosis and 25 (9.8%) cirrhosis
- At their first AUS measurement, 96 (34.2%) participants had hepatomegaly, and 30 (12.1%) showed periportal fibrosis compatible with schistosomiasis
- Over a median follow-up of 49 months (interquartile range [IQR] 24-71), the median number of AUS was 6.4 per person (IQR 3-10), or 1.7 per person-year (IQR 1-2)
- A liver lesion >1cm was detected in five (1.8%) individuals at the first AUS and in 18 (6.4%) during follow-up
- Among 23 patients with liver lesions, 14 underwent 4CT and 9 had a repeat AUS instead
- Among 14 participants with a 4CT, 8 were hemangiomas, 2 liver cysts, and 3 regenerative liver nodules and one lesion was not confirmed
- None of the liver lesions showed features of a HCC

Figure 1. Flow chart of study participants

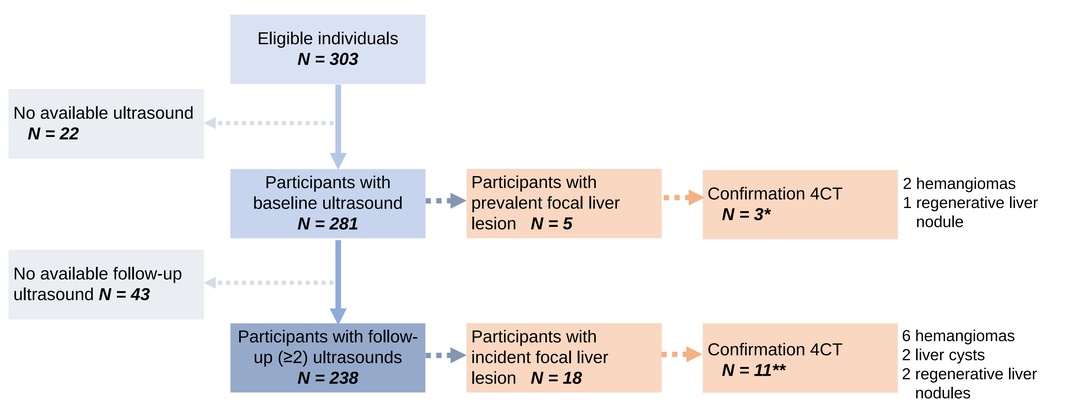

4CT, four-phase Computer Tomography (4CT)
*4CT scans were performed during follow-up as technique of 4CT was only introduced in 2018, 2 patients had a repeat AUS instead
** 7 patients had a repeat AUS instead

Figure 2: Hemangiomas were the most common lesions on four-phase Computer Tomography

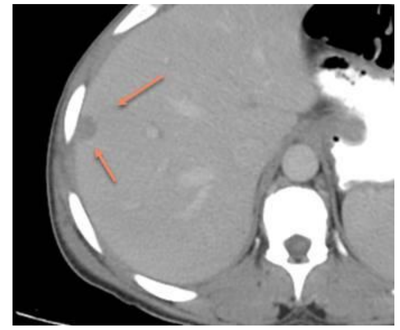

Confirmatory four-phase CT scan of a 12cm measuring lesion in the right lobe with no arterial hyperperfusion, suspicious for an hemangioma (arrow).

CONCLUSIONS

- During the first four years of HCC screening, the uptake of 6-monthly AUS was satisfactory
- 4CT confirmation was done in two-thirds of participants with liver lesions > 1 cm
- Over 1,075 py, no incident cases of HCC were diagnosed
- Future studies should evaluate the cost-effectiveness of HCC screening for people with HIV/HBV on ART

References

[1] LI-RADS ACoRCo. Liver Imaging Reporting and Data System, Version 2017. Available at: https://www.acr.org/Clinical-Resources/Reporting-and-Data-Systems/ LI-RADS (accessed 31 January2021)

ADDITIONAL KEY INFORMATION

Contact: Riebensahm,Carlotta, carlotta.Riebensahm@insel.ch

This work was funded by the Swiss Cancer League (Grant number KLS-4879-08-2019). GW was supported by a Professorship grant from the Swiss National Science Foundation (grant number PP00P3_211025). HIV/HBV cohort was also supported by NIH grant # K01TW009998 (to Vinikoor).

Contact: Author Name, email@ispm.unibe.ch; www.iedea-sa.org

The International Epidemiology Databases to Evaluate AIDS (IeDEA) is supported by the U.S. National Institutes of Health's National Institute of Allergy and Infectious Diseases, the Eunice Kennedy Shriver National Institute of Child Health and Human Development, the National Cancer Institute, the National Institute of Mental Health, the National Institute on Drug Abuse, the National Heart, Lung, and Blood Institute, the National Institute on Alcohol Abuse and Alcoholism, the National Institute of Diabetes and Digestive and Kidney Diseases, the Fogarty International Center, and the National Library of Medicine: Asia-Pacific, U01AI069907; CCASAnet, U01AI069923; Central Africa, U01AI096299; East Africa, U01AI069911; NA-ACCORD, U01AI069918; Southern Africa, U01AI069924; West Africa, U01AI069919. Informatics resources are supported by the Harmonist project, R24AI24872. This work is solely the responsibility of the authors and does not necessarily represent the official views of any of the institutions mentioned above.

IeDEA-Southern Africa Steering Committee: Matthias Egger (co-PI), University of Bern, Switzerland; Mary-Ann Davies (co-PI), University of Cape Town, South Africa; Gary Maartens, Aid for AIDS, South Africa; Carolyn Bolton, Centre for Infectious Disease Research in Zambia (CIDRZ), Zambia; Robin Wood, Gugulethu (Desmond Tutu HIV Centre), South Africa; Nosisa Sipambo, Harriet Shezi Children's Clinic, South Africa; Frank Tanser, Hlabisa (Africa Health Research Institute), South Africa; Jonathan Euvrard, Khayelitsha ART Programme, South Africa; Geoffrey Fatti, Kheth'Impilo AIDS Free Living, South Africa; Safari Mbewe, Lighthouse Trust, Malawi; Mazvita Muchengeti, National Cancer Registry (National Health Laboratory Service), South Africa; Cleophas Chimbetete, Newlands Clinic (Ruedi Luethy Foundation Zimbabwe), Zimbabwe; Karl Technau, Rahima Moosa Mother and Child Hospital, South Africa; Brian Eley, Red Cross War Memorial Children's Hospital, South Africa; Irene Ayakaka, SolidarMed Lesotho; Idivino Rafael, SolidarMed Mozambique; Cordelia Kunzekwenyika, SolidarMed Zimbabwe, Matthew P Fox, Themba Lethu Clinic, South Africa; Hans Prozesky, Tygerberg Hospital, South Africa; Andrew Boulle, Western Cape Provincial Health Data Centre.