Delayed Positivization of Non-lesion Specimens among Individuals with Mpox

291

Angelo Roberto Raccagni[1], Davide Mileto[2], Alberto Rizzo[2], Nicola Gianotti[3], **Vincenzo Spagnuolo**[3], Caterina Candela[1], Elena Bruzzesi[1], Riccardo Lolatto[3], Benedetta Trentacapilli[1], Emanuela Messina[3], Maria Rita Gismondo[2], Antonella Castagna[1,3], Silvia Nozza[1,3]

[1]Vital-Salute San Raffaele University, Milan, Italy [2]Laboratory of Clinical Microbiology, Virology and Bioemergencies, Luigi Sacco Hospital, Milan, Italy [3]Infectious Diseases Unit, San Raffaele Scientific Institute, Milan, Italy

BACKGROUND

- Viral dynamics of non-lesion mpox specimens is uncertain, with possible community implications regarding mpox transmission.
- The aim of this study was to investigate the occurrence of delayed positivization of non-lesion specimens among individuals diagnosed with mpox with mpox positive lesions at time of diagnosis.

METHODS

- We included individuals diagnosed with mpox at the Infectious Diseases Unit of San Raffaele Scientific Institute, Milan, Italy.
- Time study: from May 2022 to October 2022.
- All individuals had mpox positive cutaneous lesions at time of mpox diagnosis.
- Delayed positivization was defined as mpox detection at virologic re-evaluation in a non-lesion specimen which was previously negative at time of mpox diagnosis.
- Plasma (Pl), urines (Ur), seminal fluids (Sf), oropharyngeal (Op) and anal (An) swabs were collected among all people regardless of which symptoms were present or the site of mpox involvement.
- Individuals were virologically re-assessed until mpox virologic clearance.
- RT-PCR (RealStar® Orthopoxvirus PCR Kit 1.0 – Altona diagnostics) targeting *variola virus* and *non-variola* Orthopoxvirus species (*cowpox, mpox, raccoonpox, camelpox, vaccinia virus*) was used to detect non-variola DNA on all samples.
- Mpox cycle thresholds (Ct) are presented.
- RT-PCR targeting mpox virus DNA (Liferiver - SHANGHAI ZJ BIO-TECH CO., LTD) subsequently confirmed mpox infections.

RESULTS

- Overall, 1836 total samples from 140 MSM diagnosed with mpox were considered.
- Non-lesion specimens were 1246: 478 were positive for mpox and 768 negative for mpox.
- Viral dynamics of non-lesion specimens negative at time of mpox diagnosis are illustrated in Figure 1.
- Observed delayed positivizations were 24: 11 Op, 5 Pl, 4 Ur, 3 Sf, 1 An.
- These occurred among 14/140 (10%) of included individuals.
- Among individuals with delayed positivization, the median time to mpox diagnosis from symptoms onset was 2 days (interquartile, IQR 1-3, range 1-5).
- All individuals with delayed positivization were already in care at our center for HIV or PrEP, half were sexual contacts of known mpox cases.
- Among all individuals appearance of new mpox cutaneous lesions was documented following mpox diagnosis.

FIGURE 1

Mpox testing dynamics at virologic re-evaluation of non-lesion specimens which tested negative at mpox diagnosis; all individuals had positive mpox cutaneous lesions at time of mpox diagnosis.
Left. Non-lesion specimens which tested negative at mpox diagnosis (Negative).
Right. Viral dynamics at virologic re-evaluation (Positive or Negative).

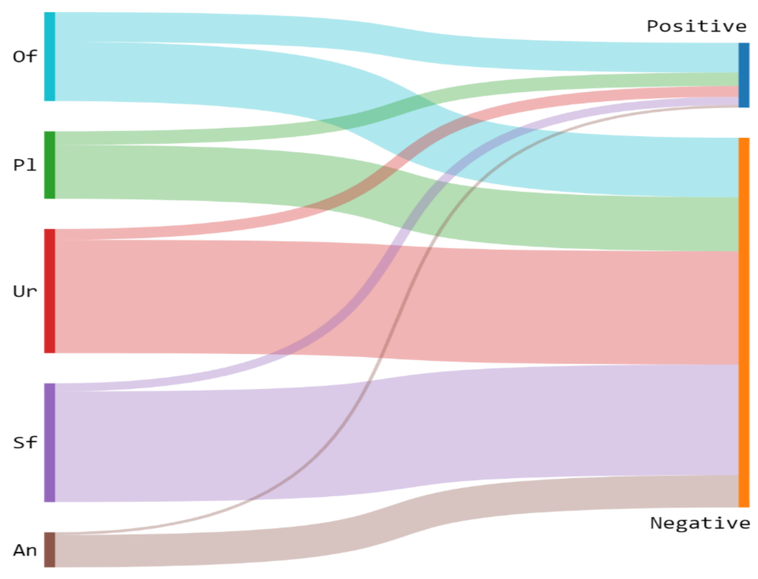

- Median cycle thresholds (Ct) of samples at time of delayed positivazion were: Op 31 (IQR 26-33), Pl 34 (IQR 33-36.5), Ur 33 (IQR 32-35), Sf 36 (IQR 35-37), and An 36.
- Median days to positivization from mpox diagnosis were: Op 7 (IQR 7-9), Pl 7 (IQR 3.5-10), Ur 7 (IQR 6.5-8), Sf 9 (IQR 8-10), and An 7.
- In Of, Ur, Sf, and An samples with delayed positivization, plasma was already positive at time of mpox diagnosis (median Ct 34, IQR 33-35).
- The median Ct of mpox lesions at time of mpox diagnosis was 24 (IQR 19-28), at time of delayed positivization 20.5 (IQR 17-25).

CONCLUSIONS

- Delayed positivization can occur in non-lesion specimens among individuals diagnosed with mpox.
- High Ct values, positivization at first virologic re-evaluation and more often at the oropharyngeal site were observed.
- We hypothesize that these individuals received a prompt mpox testing given that they were already in care at our center, most were contacts of known mpox cases and the short time interval from the onset of symptoms and mpox testing.
- We suggest that delayed positivization followed bloodstream viral dissemination, as all had mpox positive plasma at time of mpox diagnosis
- Given the community implications on transmission, these data reinforce the need of repeated mpox testing on non-lesion specimens.

CONTACT INFORMATION

raccagni.angelo@hsr.it; spagnuolo.vincenzo@hsr.it