Immunological Biomarkers Associated With Anal Dysplasia in People Living With HIV

565

Joaquín Burgos[1*], **Cristina Mancebo**[1,3], Núria Massana[1,3], Antonio Astorga-Gamaza[1], Stefania Landolfi[2], Adrian Curran[1], Jorge García[1], Vicenç Falcó[1], María J. Buzón[1], Meritxell Genescà[1*]

[1]Infectious Diseases Department, Vall d'Hebron Hospital Universitari, Institut de Recerca (VHIR), Barcelona, Spain, [2]Pathology Department, Vall d'Hebron Hospital Universitari, Universitat Autònoma de Barcelona, Barcelona, Spain

[3]This authors contributed equally *Corresponding authors: jburgos@vhebron.net (J.B.) and meritxell.genesca@vhir.org (M.G.)

BACKGROUND

Identifying local immunological mechanisms possibly involved in the development of dysplasia and progression to anal cancer could be critical for prevention and treatment of precancerous lesions, as Squamous intraepithelial lesion (SIL), in people at high risk like men who have sex with men (MSM) living with HIV.

METHODS

A cross-sectional study of 44 MSM living with HIV and ART-suppressed was performed. 54 anorectal biopsies were obtained for histological analysis and for determining their immunological environment, comparing pathological (LSIL/ HSIL) samples with non-pathological samples. Selected biomarkers were confirmed by immunohistochemistry.

Screening for anal dysplasia and possible biomarkers

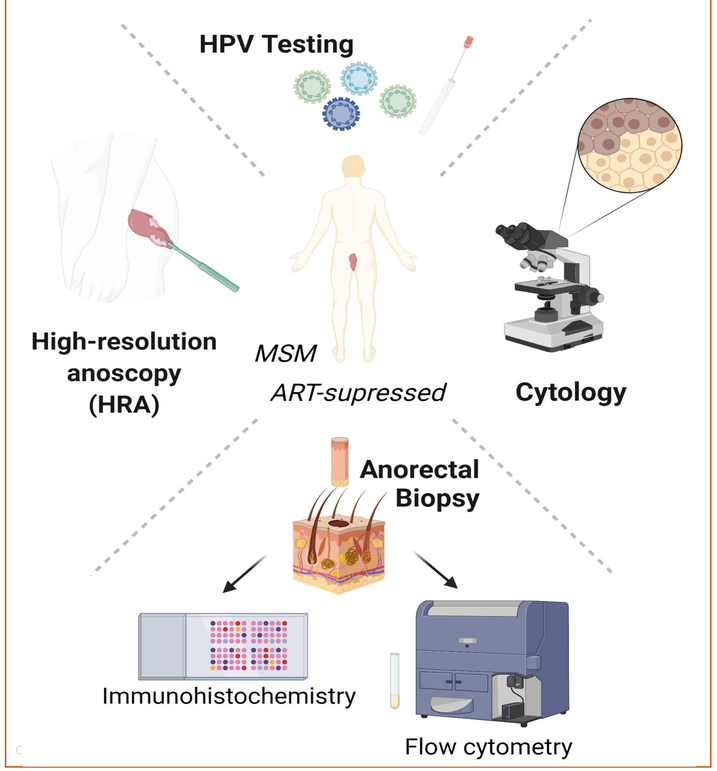

Pathological (L/HSIL) samples are characterized by: Enriched immune suppressive environment

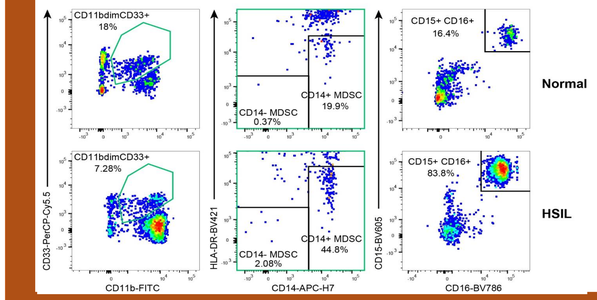

Neutrophil infiltration, defined as $CD15^{+}CD16^{+}$ cells, gradually increases as the anal lesions progresses.

Depletion of resident antiviral cells

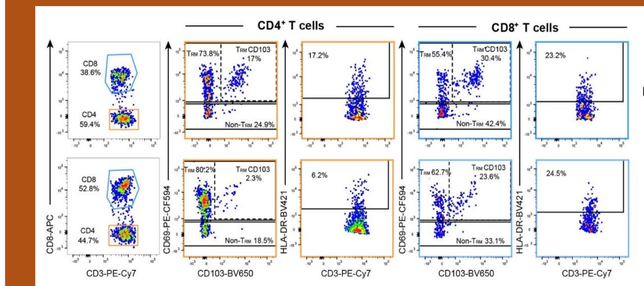

Resident Memory $CD103^{+}$ $CD8^{+}$/$CD4^{+}$ T cells were less frequent in pathological biopsies.

RESULTS

Immunohistochemistry

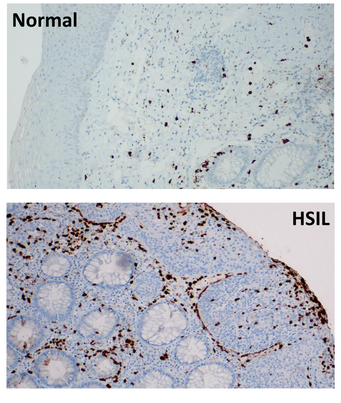

$CD15^{+}$ cells present in epithelium and underlying lamina propria.

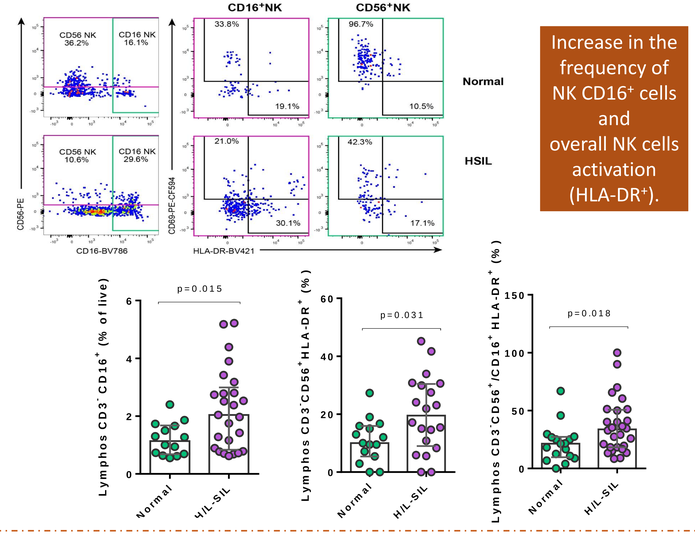

Increase in the frequency of NK $CD16^{+}$ cells and overall NK cells activation ($HLA\text{-}DR^{+}$).

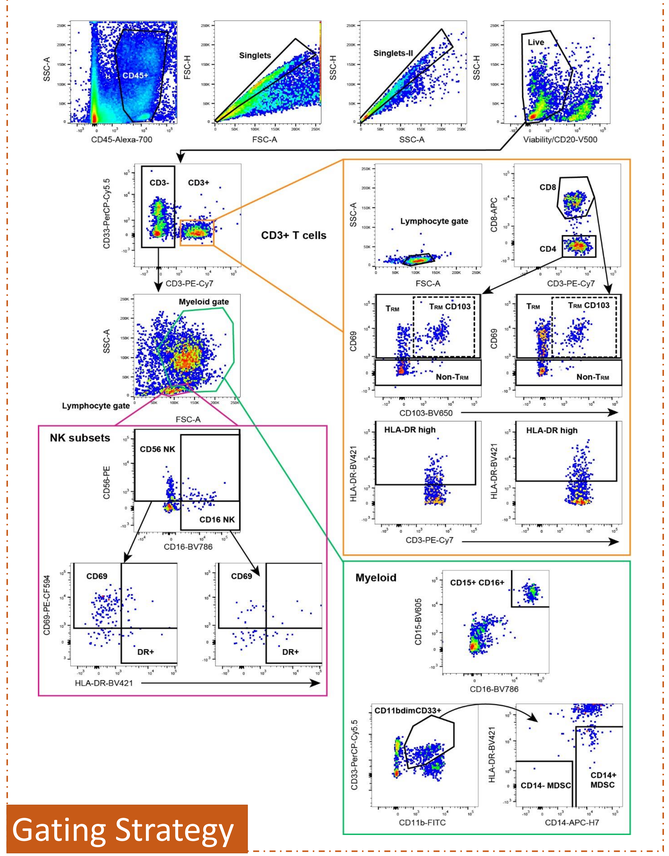

Gating Strategy

CONCLUSIONS

- The balance between resident effectors and inflammatory subsets was tilted towards the second in pathological anorectal samples.
- Neutrophil infiltration, determined by CD15 staining, may represent a valuable biomarker to determine the dysplasia's grade.

ADDITIONAL KEY INFORMATION

cristina.mancebo@vhir.org, * jburgos@vhebron.net, *meritxell.genesca@vhir.org

Acknowledgments: This work was primarily supported by grants from the Spanish Health Institute Carlos III (ISCIII, PI16/00736 and PI20/00160) and additionally supported by Spanish AIDS network Red Temática Cooperativa de Investigación en SIDA (RD16/0025/0007), the European Regional Development Fund (FEDER), the Fundació La Marató TV3 (201814-10FMTV3) and the Gilead fellowships GLD18/00008.