HIV and Addictions Research Program

Serum Neurofilament As a Marker of White Matter Injury In HIV Disease

00413

Christina S. Meade, Sheri L. Towe, David M. Murdoch, Ryan P. Bell
Duke University School of Medicine, Durham, NC, USA

Background

- Neurocognitive impairment (NCI) related to brain injury remains a common comorbidity in HIV disease.
- White matter degradation partly reflects legacy effects of untreated HIV infection.
- Despite effective antiretroviral therapy, persistent immune activation may contribute to further degradation.
- Neurofilament light (NFL) is a biomarker of axonal injury that can be measured in biofluids.
- NFL concentrations in blood can distinguish persons based on HIV and NCI status, but correlations with MRI markers of neuronal injury have not been reported.

Specific Aim

- To examine the correlation of NFL, measured in serum, to voxel-wise measures of white matter integrity captured using diffusion-weighted MRI.

Methods

- Sample: 108 adults with chronic HIV disease on antiretroviral therapy and with suppressed HIV viral load
  - Exclusions: perinatal infection, major neurological disorder, head trauma, severe mental illness, systemic autoimmune disease, immunomodulatory medication
- MRI protocol: 3T GE Discovery MR750 scanner
  - Sequence: diffusion sensitized parallel echo-planar in axial plane, 86 unique directions, 2 mm^3 voxels
  - Metrics: fractional anisotropy (FA), axial diffusivity (AD), and radial diffusivity (RD)
- Peripheral blood: serum samples
  - NFL: Simoa® NF-Light Advantage Kit (Quanterix)
  - sCD14: CD14 Quantikine ELISA Kit (R&D Systems)

Table 1. Sample characteristics

Age in years, M (SD)	45.44 (9.66)
Cis-female gender[1], %	19.4
African-American race, %	75.9
Education in years, M (SD)	13.81 (2.50)
Years since HIV diagnosis, M (SD)	14.60 (7.84)
Nadir $CD4^+$ T-cell count, MED (IQR)	195.50 (273)
Current $CD4^+$ T-cell count, MED (IQR)	755.50 (508)

[1] For all participants, biological sex matched gender

Neurofilament light (NFL) is a useful blood biomarker of axonal degradation in the brain among people with HIV

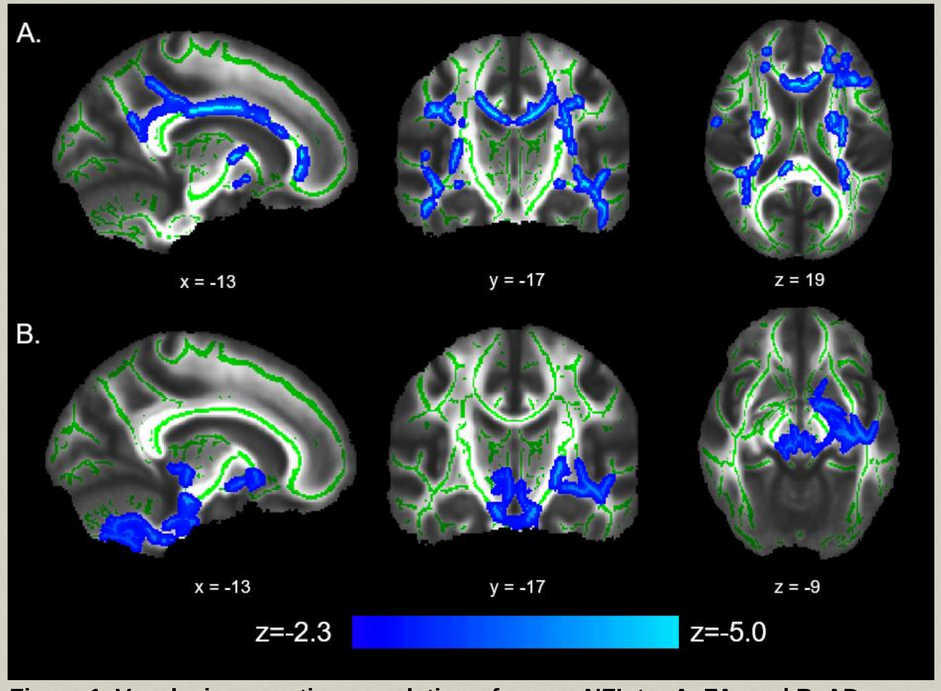

Figure 1. Voxel-wise negative correlation of serum NFL to: A. FA, and B. AD, using tract based spatial statistics, controlling for age (p<.05, Threshold-Free Cluster Enhancement correction). NFL was unrelated to RD.

Results

Table 2. White matter clusters

Fractional anisotropy (FA)	MNI coordinates at max	No. of voxels
L middle of corpus callosum	-10, -14, 29	5,414
L inferior frontooccipital fasciculus	-36, -8, -14	3,232
R frontopontine	29, -9, 24	2,388
R superior longitudinal fasciculus	42, -18, 30	1,527
R vertical occipital fasciculus	24, -57, -1	653
R corpus callosum	23, 31, 16	245
L superior longitudinal fasciculus	-48, -28, 24	115
R forceps minor	16, 38, -10	93
L middle of corpus callosum	-18, -2, 34	42
Anterior commisure	5, 5, -6	12
Axial diffusivity (AD)		
L fornix	-24, -8, -16	6252

Significant clusters were extracted using the "cluster" command in FSL.

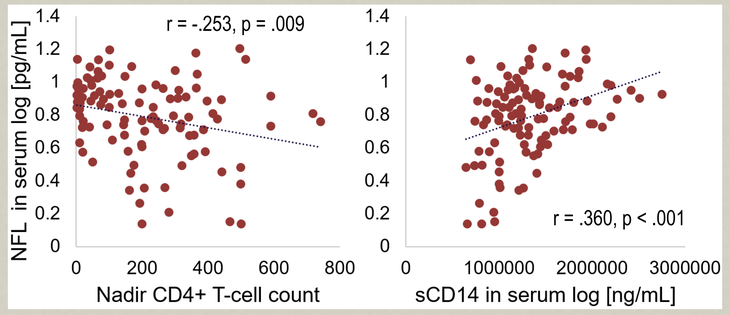

Figure 2. Scatter plots of NFL correlations to clinical indicators

Conclusions

- As expected, NFL correlated negatively with nadir CD4 T-cell count (legacy effects) and positively with current sCD14 (persistent immune activation).
- NFL mapped with FA in corpora callosa and projection tracts, as well as AD in subcortical tracts, consistent with axonal damage.
- NFL is a useful blood marker of white matter integrity in people with HIV, but effects cannot be localized to specific tracts.
- Neuroimaging, in combination with laboratory tests, is an invaluable tool for visualizing structural changes in HIV disease.

Miscellaneous

- Funding: R01-DA043241
- Contact: christina.meade@duke.edu

Duke University School of Medicine