Unanticipated Increases in Fatty Liver in HIV NAFLD Patients with Eplerenone

#634

Chloe S. Chaudhury[1], Julia B. Purdy[2], Chia-Ying Liu[2], Caryn G. Morse[2], Takara Stanley[3], David Kleiner[4], Colleen Hadigan[1]

[1]National Institute of Allergy and Infectious Diseases, NIH, Bethesda, MD, [2]NIH Clinical Center, NIH, Bethesda, MD, [3]Massachusetts General Hospital, Boston, MA, [4]National Cancer Institute, NIH, Bethesda MD

BACKGROUND

- Metabolic disturbances including insulin resistance, diabetes, dyslipidemia , and visceral adipose tissue (VAT) are increased among persons living with HIV infection.
- Excess VAT stores are associated with hepatic steatosis in HIV-infected individuals.
- Aldosterone, a known mineralocorticoid receptor (MR) agonist, is increased in association with increased VAT and decreased insulin sensitivity.
- The role of aldosterone and MR activation linked to excess VAT could offer a novel treatment strategy to target metabolic disturbances, including hepatic steatosis, observed in individuals with visceral fat accumulation.
- Promising animal models demonstrate marked reductions in fasting glucose, insulin, hepatic steatosis, and inflammation with MR antagonist targeting the aldosterone axis.
- Therefore we conducted a proof-of concept open-label 24 week study to evaluate the effect of eplerenone on hepatic steatosis in patients with HIV infection and increased liver fat. The primary endpoint was change in hepatic fat by MR spectroscopy at 24 weeks.

METHODS

- Subject Inclusion Criteria
  - hepatic steatosis at baseline, defined as hepatic fat ≥ 5% by magnetic resonance spectroscopy (MRS).
  - a waist circumference >102 cm for men or >88 cm for women
  - a stable suppressive antiretroviral therapy regimen for at least three months
- Subject Exclusion Criteria
  - uncontrolled hypertension or diabetes,
  - current or recent steroid use,
  - contraindicated medications
  - co-infection with Hepatitis C virus or other serious infections,
  - history of a serious cardiovascular event

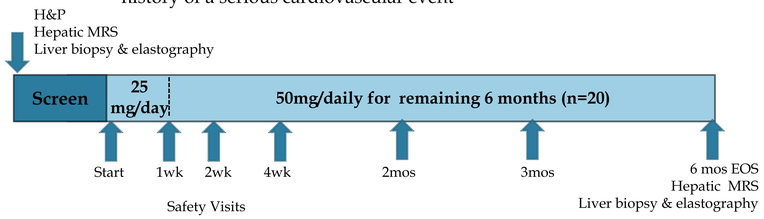

- Five subjects received eplerenone at 25 mg daily for one week, followed by an increase to 50 mg daily for 23 weeks (no adverse effects on serum potassium, creatinine, or eGFR).
- The study was terminated early, after enrollment of only five subjects, due to unexpected observations in hepatic fat content.
- Participants were invited to return 1-2 months following discontinuation of eplerenone for a follow-up MRS off eplerenone therapy.

RESULTS

Baseline Characteristics

Subject	Age (years)	Sex	BMI (kg/m²)	CD4 (cells/mL)	ARVs
1	61	M	30.6	860	ABC/3TC/DTG
2	37	F	34.8	1305	ABC/3TC/DTG
3	62	M	27.8	422	ABC/3TC/DTG
4	50	F	42.8	1341	ABC/FTC/TDF
5	60	M	32.3	759	ABC/3TC/DTG
Total, Median	60	-	32.3	860	-

- We observed unexpected significant increases in hepatic fat at week 24 for all participants (mean increase 13.0 ± 7.3%, p=0.02) (Figure 1).
- Increases in steatosis were accompanied by a tendency for transaminase values to decrease: ALT mean change -14 ± 16 IU/L (p=0.14) (Figure 3) and AST mean change -12 ± 14 IU/L (p=0.17).

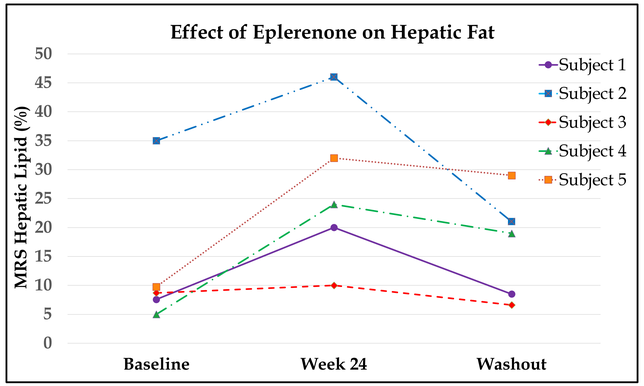

Figure 1. Hepatic lipid content changes by MR spectroscopy in each participant at baseline, after 24 weeks on eplerenone (p=0.02) and washout (1-2 months after termination of study drug, p=0.08).

- We observed an initial rise in aldosterone from baseline to week 4 for all participants, as expected; however, serum aldosterone levels did not increase significantly at week 24 vs. baseline (mean increase 22.2 ± 37.1 ng/dL, p=0.30).
- Systolic blood pressure tended to decrease (mean change -11.2 ± 16.3 mmHg, p=0.24), with minimal change in diastolic blood pressure (mean change 2.6 ± 7.5 mmHg, p=0.53).
- There was a non-significant increase in VAT as estimated by DEXA, with mean change of 101 ± 153 mL (p=0.26).
- Participants, however, had significant decreases in waist circumferences (mean change -3.14 ± 1.51 cm, p=0.01).
- There were no consistent or significant alterations in potassium, creatinine, HbA1c, fasting glucose, total cholesterol, triglycerides, free fatty acids, renin, waist-to-hip ratio, or CD4 count at the week 24 visit.

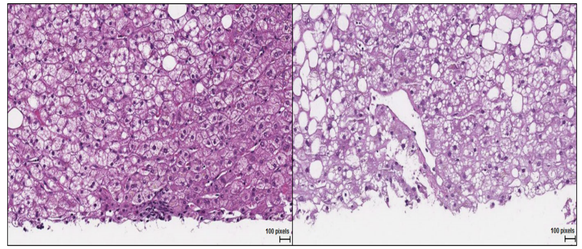

Figure 2. Representative liver histopathology (H&E stain) for subject 2 at baseline (left, steatosis grade 1) and week 24 on eplerenone (right, steatosis grade 3).

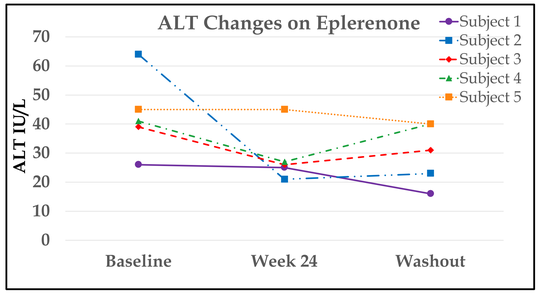

Figure 3. Alanine aminotransferase changes in each participant at baseline, 24 weeks on eplerenone, and washout.

CONCLUSIONS

- The current study presents evidence to reconsider MR antagonists for treatment of NAFLD in HIV-infected patients or the general population.
- While our study was small and had an open-label design, the results were surprising and clinically significant after only 24 weeks of drug administration.
- The potential harmful effect of eplerenone on hepatic steatosis occurred without associated increases in liver transaminases.
- MR blockade with eplerenone may increase circulating renin, angiotensin II, and aldosterone. Effects of these hormones that are independent of the MR may be mechanisms by which eplerenone increased liver fat content.
- Though not statistically significant, VAT increased with eplerenone and may therefore explain in part the unexpected increases observed in hepatic steatosis.
- The only laboratory test changes which seemed to signal the increases in hepatic steatosis were the decreases in SHBG levels at week 24 in four of the five participants. Low levels of SHBG are associated with fatty liver disease.
- Additional research is needed to determine the pathophysiologic mechanism behind these unanticipated observations.

MGH 1811 MASSACHUSETTS GENERAL HOSPITAL

NIH National Institute of Allergy and Infectious Diseases