# sCD163 in Plasma Correlates with Increased Intima-Media Thickness and Fibrosis in Aorta and Heart With HIV Infection


**Joshua A. Walker[1], Graham A. W. Beck[1], Andrew D. Miller[2], Tricia H. Burdo[1], and Kenneth C. Williams[1]**

[1]Department of Biology, Boston College, Chestnut Hill, MA

[2]Cornell University, College of Veterinary Medicine, Department of Biomedical Sciences, Section of Anatomic Pathology, Ithaca, NY


Poster #753

## Introduction

HIV-associated mortality and morbidity has decreased due to widespread anti-retroviral treatment (ART)[1,2]. However, HIV+ individuals have a two-fold greater risk of cardiovascular disease (CVD) compared to the uninfected population[3]. This increased risk cannot be accounted for by traditional risk factors and could be due to a combination of ART[4], viral infection, and chronic macrophage inflammation. While increased monocyte/macrophage accumulation occurs in the ascending aorta with HIV infection and correlates with the number of non-calcified, vulnerable plaques[5], overall the role of macrophages is understudied. Using a SIV-infection, CD8-lymphocyte depletion model of AIDS we have shown rhesus macaques have increased numbers of CD163+, CD68+, and MAC387+ macrophages in the heart that correlates with increasing percentage of collagen (a marker of fibrosis)[6], suggesting that monocytes/macrophages play a role fibrosis. Additionally we, and others, have shown that levels of soluble CD163 (sCD163), a marker of monocyte/macrophage activation, are increased in acute and chronically infected individuals, and levels of sCD163 correlate with the percentage of non-calcified, vulnerable plaques[7]. These observations suggest that immune activation and macrophage accumulation with HIV infection potentially play a role in the development of cardiac pathology. In this study we examined the role of macrophage activation and accumulation in the development of cardiovascular pathology with HIV infection. We examined if levels of sCD163 correlate with increased fibrosis and aortic intima-media thickness. Additionally, we examined if tilmanocept , an *in vivo* diagnostic imaging agent that has been used to accurately detect sentinel lymph nodes in patients with head and neck squamous cell carcinoma[8] , can be used to assess macrophage inflammation in cardiac tissues and aorta with HIV infection.

## Study Design

We used matched cardiac tissue (left ventricle) and aorta tissue samples from ten HIV- and ten HIV+ individuals with CD4 counts less than 200 cells/mL. Tissues matched from HIV- individuals were provided by the National Disease Research Institute (NDRI) and tissues from HIV+ individuals were provided by the National NeuroAIDS Tissue Consortium (NNTC). Antibodies recognizing CD163, CD68, MAC387 and CD206 on macrophages and CD3 on T-lymphocytes were used to stain cardiac and aorta tissues. Cardiac tissues were graded blindly by a pathologist based on the degree of inflammation, degeneration, and fibrosis and matched aorta tissues were graded based on the degree of inflammation, aortic degeneration and atherosclerosis, and scored as mild, moderate, or severe. Normal sections were scored as having no significant findings (NSF). The degree of fibrosis in cardiac tissues was assessed using a modified Massons trichrome stain. Aortic intima-media thickness (aIMT), a surrogate marker of cardiovascular disease was measured using an elastic stain kit. Additionally, levels of sCD163 in plasma were measured by ELISA (Trillium Diagnostics).

## References


1. Palella, F. et al. *The New England Journal of Medicine*. 1998, 338:13.
2. Coquet, I. et al. *Critical Care*. 2010, 14:3.
3. Hemkens, L. and Bucher, C. *The European Heart Journal*. 2014, 35:21.
4. Holmberg, S. et al. *The Lancet*. 2002, 360:9347.
5. Pereyra, F. et al. *AIDS*. 2012, 26:18.
6. Walker, J. et al. *AIDS Research and Human Retroviruses*. 2014. 30:7.
7. Burdo, T. et al. *Journal of Infectious Diseases*. 2011. 204:1.
8. Agrawal, A. et al. *Annals of Surgical Oncology*. 2015. epub, ahead of print


## Table 1

Cardiovascular Pathology of the Left Ventricle

| Group | n | Pathology | | |
|---|---|---|---|---|
| | | Inflammation | Fibrosis | Cardiomyocyte Degeneration |
| HIV- | 10 | 1, NSF<br>6, Mild<br>3, Moderate | 3, NSF<br>5, Mild<br>2, Moderate | 7, Mild<br>3, Moderate |
| HIV+ | 10 | 2, Mild<br>5, Moderate,<br>3, Severe | 3, Mild<br>4, Moderate<br>3, Severe | 4, Mild<br>4, Moderate<br>2, Severe |

**HIV infection resulted in an increase in severity of inflammation, fibrosis, and cardiomyocyte degeneration in cardiac tissues.** Sections of cardiac tissues were blindly graded by a pathologist. Normal cardiac tissues were graded as no significant findings (NSF). The degree inflammation, fibrosis, an cardiomyocyte degeneration, was scored as either being mild, moderate, or severe.

## Table 2

Significant Increases in Macrophage Numbers in Cardiac Tissues with HIV Infection

| Immune Markers | HIV- (n=10) | HIV+ (n=10) | *p* value | Fold Change |
|---|---|---|---|---|
| CD163 | 32.84±6.46 | 80.26±7.93 | ** | 2.44 |
| CD68 | 25.39±4.67 | 49.20±3.63 | ** | 1.93 |
| MAC387 | 11.63±1.66 | 22.64±1.63 | * | 1.94 |
| CD206 | 35.28±5.25 | 82.13±4.22 | *** | 2.32 |
| CD3 | 6.41±5.71 | 15.72±8.51 | - | - |

**With HIV infection, we found significant increased numbers of CD163+, CD68+, MAC387+ and CD206+ macrophages in cardiac tissues with HIV infection compared to controls.** There were no differences between groups in numbers of CD3+ T-lymphocytes. *p* values were calculated by comparing the mean number of positive cells for HIV- and HIV+ using a nonparametric t-test. (* p<0.05, ** p<0.01, ***p<0.005). of HIV+ sections compared to controls. There were no significant differences between the numbers of CD3+ T-lymphocytes in either group. . Numbers represent the mean number of positive cells (cells/mm$^2$) ± standard error of the mean based on counts from 20 non-overlapping fields using 20X objective.

## Figure 1

Increased Fibrosis with HIV Infection Correlates with Increased Numbers of CD163+, CD68+, MAC387+, and CD206+ Macrophages

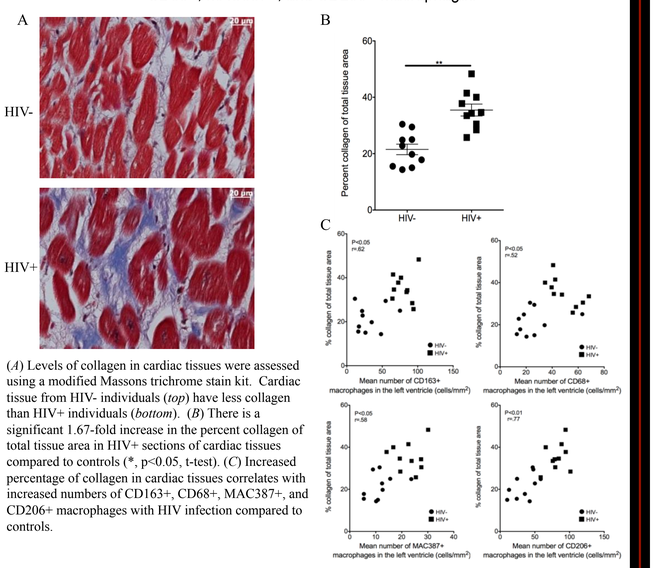


(*A*) Levels of collagen in cardiac tissues were assessed using a modified Massons trichrome stain kit. Cardiac tissue from HIV- individuals (*top*) have less collagen than HIV+ individuals (*bottom*). (*B*) There is a significant 1.67-fold increase in the percent collagen of total tissue area in HIV+ sections of cardiac tissues compared to controls (*, p<0.05, t-test). (*C*) Increased percentage of collagen in cardiac tissues correlates with increased numbers of CD163+, CD68+, MAC387+, and CD206+ macrophages with HIV infection compared to controls.

## Table 3

Cardiovascular Pathology of the Aorta

| Group | n | Pathology | |
|---|---|---|---|
| | | Inflammation | Aortic Degeneration |
| HIV- | 10 | 2, NSF<br>5, Mild<br>3, Moderate | 6, Mild<br>4, Moderate |
| HIV+ | 10 | 1, NSF<br>2, Mild<br>3, Moderate<br>1, Severe | 5, Mild<br>4, Moderate<br>1, Severe |

**HIV infected individuals have an increase in the severity of inflammation and degeneration in the aorta.** Sections of aorta were blindly graded by a pathologist. The degree inflammation, aortic degeneration, and atherosclerosis, was scored as either being mild, moderate, or severe. Aortic degeneration was based on the alignment of smooth muscle fibers in the tunica intima. Normal sections of aorta were graded as no significant findings (NSF).

## Table 4

Significant Increases in Macrophage Numbers in Aorta with HIV Infection

| Immune Markers | HIV- (n=10) | HIV+ (n=10) | *p* value | Fold Change |
|---|---|---|---|---|
| CD163 | 22.95±3.66 | 46.78±4.51 | * | 2.03 |
| CD68 | 16.15±1.96 | 27.65±3.02 | * | 1.71 |
| MAC387 | 7.98±1.36 | 15.35±1.43 | * | 1.92 |
| CD206 | 12.74±2.28 | 25.18±2.58 | * | 1.97 |
| CD3 | 2.32±6.71 | 5.04±7.11 | - | - |

**With HIV infection we found significant increases in the numbers of CD163+, CD68+, MAC387+ and CD206+ macrophages in the aorta of HIV+ sections compared to controls.** There were no significant differences between the numbers of CD3+ T-lymphocytes in either group. *p* values were calculated by comparing the mean number of positive cells for HIV- and HIV+ using a Mann-Whitney nonparametric t-test.(* p<0.05). Numbers represent the mean number of positive cells (cells/mm$^2$) ± standard error of the mean based on counts from 20 non-overlapping fields using 20X objective.

## Figure 2

Increased Intima-media Thickness and Numbers of CD163+, CD68+, MAC387+, and CD206+ Macrophages in the Aorta with HIV Infection

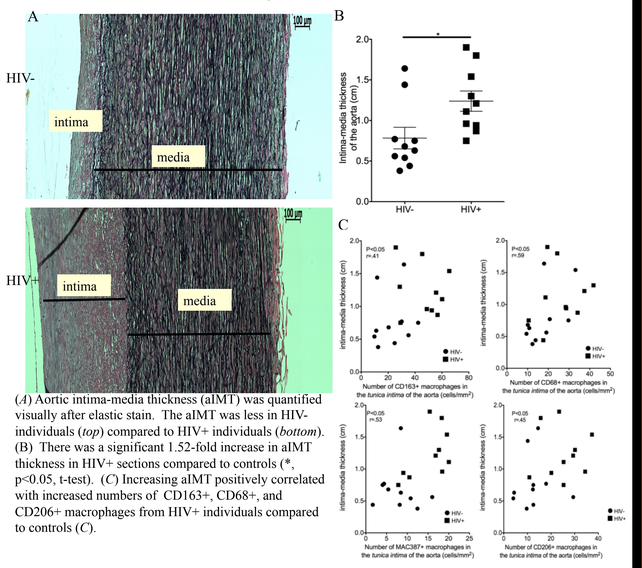


(*A*) Aortic intima-media thickness (aIMT) was quantified visually after elastic stain. The aIMT was less in HIV- individuals (*top*) compared to HIV+ individuals (*bottom*). (B) There was a significant 1.52-fold increase in aIMT thickness in HIV+ sections compared to controls (*, p<0.05, t-test). (*C*) Increasing aIMT positively correlated with increased numbers of CD163+, CD68+, and CD206+ macrophages from HIV+ individuals compared to controls (*C*).

## Figure 3

Increasing Levels of sCD163 Correlate with Increased Fibrosis and Intima-media Thickness with HIV Infection

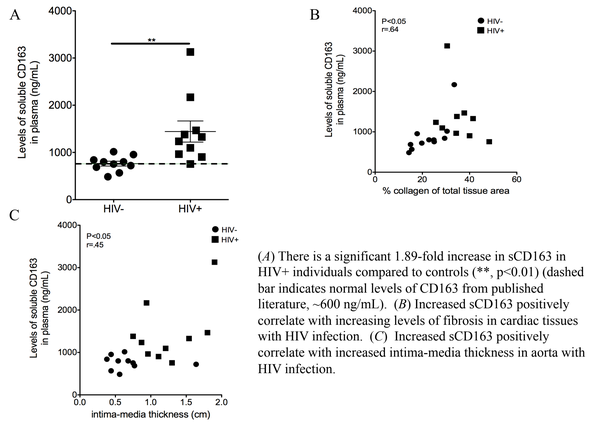


(*A*) There is a significant 1.89-fold increase in sCD163 in HIV+ individuals compared to controls (**, p<0.01) (dashed bar indicates normal levels of CD163 from published literature, ~600 ng/mL). (*B*) Increased sCD163 positively correlate with increasing levels of fibrosis in cardiac tissues with HIV infection. (*C*) Increased sCD163 positively correlate with increased intima-media thickness in aorta with HIV infection.

## Future Directions

Co-localization of Tilmanocept with CD163+ and CD206+ Macrophages in Cardiac Tissue and Aorta

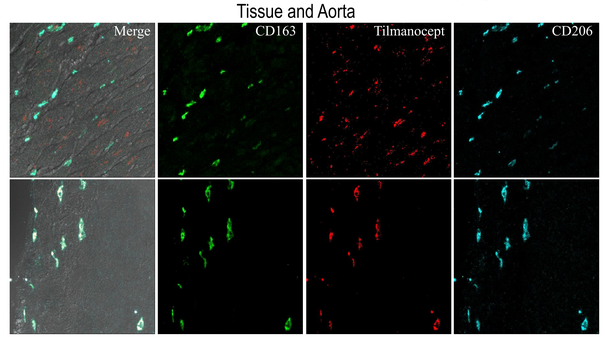


There is a high level of co-localization between CD206+ and CD163+ macrophages (74±8.51%) and co-localization between CD206+ and CD163+ macrophages and tilmanocept in cardiac tissues (73.2±6.3%) (*top*). A higher level of co-localization between CD206+ and CD163+ macrophages is seen in the aorta (93±4.3%) and co-localization between CD206+ and CD163+ macrophages and tilmanocept (82.7±8.1%). (*bottom*). Tilamnocept was provided by Navidea Biopharmaceuticals.

## Conclusions

*There are increased numbers of macrophages in cardiac tissues and aorta of HIV+ individuals compared to seronegative controls.

*There are strong correlations between increased numbers of CD163+, CD68+, MAC387+, and CD206+ macrophages and the percentage of collagen per total tissues area (fibrosis) seen in cardiac tissues and IMT in the aorta with HIV infection

*In HIV+ individuals, plasma sCD163 is elevated and correlate with and with increasing fibrosis in cardiac tissues and increasing intima-media thickness of the aorta.

*Tilmanocept, a radiolabeled probe that binds CD206+ and CD163+ macrophages could potentially assess subclinical cardiovascular disease among HIV+ individuals.

## Funding


*This work was supported by NIH R01 NS040237 (KCW) and NIMH 5002026.