Antiviral Therapy and Smoking Associated with Coronary Vessel Wall Thickening in HIV-Infected Youth

A. Unsal[1], K. Z. Abd-Elmoniem[2], S. Eshera[2], J. B. Purdy[3], R. Hazra[4], C. Hadigan[1], A. M. Gharib[2]

[1]National Institute of Allergy and Infectious Disease, [2]National Institute of Digestive and Kidney Diseases, [3]Critical Care Medicine, Clinical Center, [4]*Eunice Kennedy Shriver* National Institute of Child Health and Human Development
National Institutes of Health, Bethesda, MD

BACKGROUND

- Individuals on long-term antiretroviral therapy (ART) are at elevated risk for a number of non-AIDS related health complications, including increased cardiovascular disease (CVD) risk
- Chronic inflammation, aberrant immune activation, toxicity due to ART, and viral effects of HIV itself in addition to traditional CVD factors may contribute to increased CVD risk associated with HIV infection in young adults with perinatal infection
- Vessel wall thickness and quantification of plaque in coronary vessels may be more predictive of cardiovascular events than other indicators of CVD
- Early signs of cardiac and vascular dysfunction in asymptomatic young adults with life-long HIV infection and healthy controls were compared using CT angiography and black-blood coronary vessel wall imaging by MRI

METHODS

- Prospective cross-sectional study of 35 youth and young adults who acquired HIV in early life and 11 sex and race matched healthy controls, all free of active CVD
- Phase-sensitive dual inversion recovery black-blood vessel wall imaging was utilized for MR imaging of the proximal right coronary artery (RCA)
- CT angiography was performed for determination of coronary plaque burden and pericardial fat
- Nadir CD4 and lifetime ART exposure were characterized by review of clinical history
- Fasting laboratories included chemistry, lipid panel, CD4 T cell counts, HIV viral load, biomarkers of inflammation (e.g. d-dimer, highly sensitive CRP). Values in data tables are the mean ± SD unless otherwise indicated.

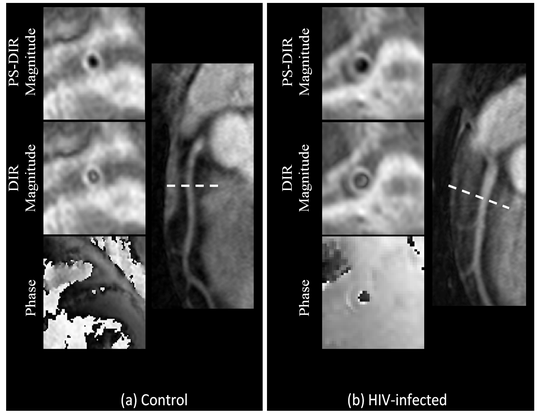

Figure 1: Phase-sensitive dual inversion-recovery (PS-DIR) black-blood vessel MR imaging of the proximal right coronary artery (RCA) in (a) a control subject and (b) an HIV-infected patient

RESULTS

Table 1: Demographic and clinical characteristics, including CT and MRI measurements, of participants.

	HIV+ (n=35)	Control (n=11)	P-value
Age, years	22 ± 4	25 ± 2	**0.007***
Sex: Male/Female (%)	54/46	27/73	0.12
BMI (kg/m²)	23.9 ± 5.7	26.1 ± 4.8	**0.047***
Ever Smoked, n (%)	10 (29)	2 (18)	0.48
Smoking Pack years	0.8 ± 2.2	0.07 ± 0.2	0.36
Systolic BP (mmHg)	123 ± 14	116 ± 6	**0.04***
Diastolic BP (mmHg)	73 ± 8	67 ± 7	**0.03***
Hypertension, n (%)	4 (11)	0 (0)	0.13
Total Cholesterol (mg/dL)	152 ± 31	177 ± 28	**0.02***
LDL (mg/dL)	89 ± 34	98 ±26	0.14
HDL (mg/dL)	47 ± 12	65 ± 12	**0.0002***
hs-CRP (mg/mL)	3.2 ± 5.3	1.7 ±1.4	0.88
Current CD4 (cells/µL)	502 ± 306	781 ± 184	**0.008***
RCA vessel wall thickness (mm)	1.32 ± 0.21	1.09 ± 0.14	**0.002***
Lumen radius (mm)	1.20 ± 0.42	1.03 ± 0.32	0.19
Lumen area (mm²)	5.15 ± 3.30	3.64 ± 2.12	0.14
Epicardial Fat (mL)	27.45 ± 16.99	21.89 ± 2.98	0.94
Pericardial Fat (mL)	51.52 ± 26.32	45.16 ± 14.10	0.80
Presence of coronary plaque, n (%)	6 (19)	5 (45)	0.09

Table 2: Clinical characteristics of the HIV+ group.

	HIV+ (n=35)
Current ARV use, n (%)	25 (71)
Duration ARV use, years	15 ± 5
CD4 < 200 (cells/µL), n (%)	5 (14)
Nadir CD4 (cells/µL)	202 ± 186
HIV RNA <50 copies/mL, n (%)	15 (43)

Regression Analyses of Variables Associated with Coronary Vessel Wall Thickness

- HIV infection (p=0.02) remained a significant independent predictor of RCA vessel wall thickness in a model including age, sex, and BMI and HIV status
- The difference in proximal RCA thickness between patients and controls remained significant (p=0.002) when HIV-infected subjects <20 years of age were excluded from our analysis to match both groups by age.
- Duration of ART (p<0.05) and smoking pack-years (p=0.01) were independent predictors of RCA wall thickness in the HIV-infected patients after adjusting for age, sex, and BMI
- Although blood pressure, age, total and HDL cholesterol and BMI differed between the controls and the HIV infected groups, none of these were correlated with RCA vessel wall thickness.
- There was also no association between vessel wall thickness and: the presence of coronary plaque, levels of CRP, d-dimer, pro-BNP, or homocysteine for either study group.

Figure 2: Box plot of RCA vessel wall thickness (mm) of control subjects vs. HIV-infected patients with a viral load of <50 copies/mL and HIV-infected patients with a viral load of >50 copies/mL.

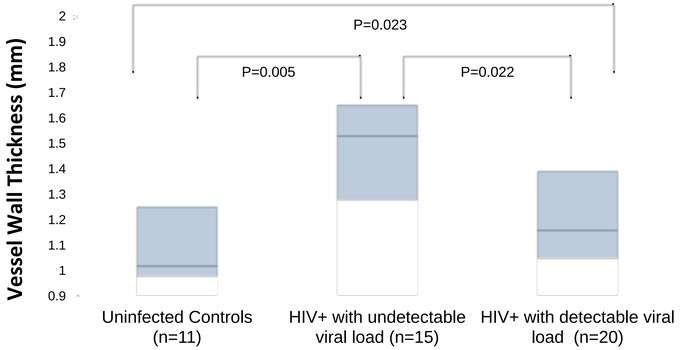

Figure 3: Vessel wall thickness (mm) as a function of duration of ART (years).

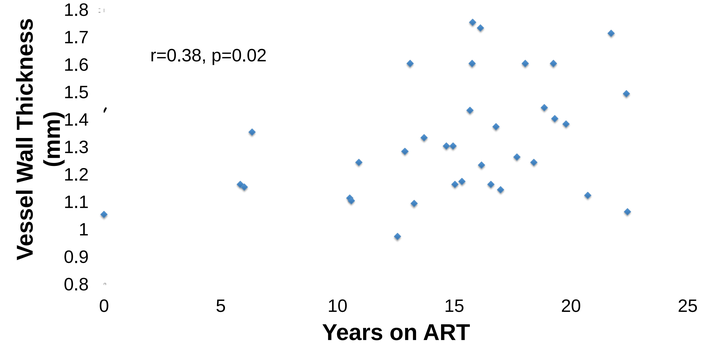

CONCLUSIONS

- Individuals infected with HIV early in life have premature vascular injury compared to healthy volunteers, as shown by coronary vessel wall thickness
- Increased duration of ART and smoking pack years were strong indicators of proximal RCA thickening in the HIV+ population
- Coronary vessel wall thickening was independent of atherosclerotic plaque, indicating that vessel wall thickening related to ART exposure occurs through a mechanism distinctive from traditional atherogenesis