Table 1: Cervical HPV versus cytology

PREVALENCE OF ANAL DYSPLASIA IN HIV-INFECTED WOMEN FROM JOHANNESBURG, SOUTH AFRICA

Bridgette J Goeieman [1], **Cynthia S Firnhaber** [1,2], **Pam Michelow**[1,4] , **Jennifer S Smith**[3], **Timothy Wilkin**[5]

[1] Right to Care, Johannesburg South Africa, [2] University of the Witwatersrand, Johannesburg, South Africa, [3] University of North Carolina, North Carolina, [4]National Health Laboratory Services, [5] Weill Cornell Medical College, New York, USA

ABSTRACT

BACKGROUND: Cervical cancer caused by oncogenic Human Papillomavirus (HPV) infection is a common cause of morbidity and mortality in HIV-infected women in Sub-Saharan Africa. HPV infection also causes anal cancer, but the incidence of anal cancer in this population is unclear. In Sub-Saharan Africa, there are no data available on the prevalence of anal HPV infection or dysplasia in HIV-infected individuals. These are the first epidemiological data on the prevalence of anal HPV infection and dysplasia in HIV-infected women from South Africa.

METHODS: Prospective cohort study of HIV-infected women age 25-65. Participants were recruited from an HIV clinic in Johannesburg, South Africa. Anal swabs were taken for conventional glass-slide cytology and oncogenic HPV testing (Digene HC2). All women with abnormal anal cytology and 20% of women with normal cytology were seen for high resolution anoscopy (HRA) with biopsy of visible lesions. Biopsies were taken at the 6 and 12 positions on anus for women without visible lesions. Women had cervical cytology and HPV specimens obtained. We summarized the baseline characteristics of this cohort using descriptive statistics. Quality assurance of HRA was done through digital pictures and discussion with a specialist.

RESULTS: A total of 88 women have been enrolled. The anal cytology results were normal in 9/88 (10%); 61/88 (72%) had low grade squamous intraepithelial lesions (SIL) or ASCUS, and 16/88 (18%) had ASC-H/high grade SIL. 84% of women had an abnormal cervical cytology defined as low grade lesions and above. Anal biopsies results are available for 66 women: 27 (31%) had negative histology, 30 (34%) had atypia or Low Grade anal intraepithelial neoplasia (AIN) and 9 (10%) had High Grade AIN. Anal biopsies were not obtained in 22 (25%). 42% of women had high risk HPV detected on anal swabs, and 36% had high risk HPV on cervical swabs. Anal high risk HPV was found in 24% of women with LSIL on anal cytology and 75% of women with HSIL/ASC-H.

CONCLUSION: We have found significant burden of anal HPV infection and abnormal anal cytology. High grade (SIL) on anal cytology was found in 18% of our women which is 2-4X higher than reports from cohorts of men who have sex with men. The observed prevalence of high grade AIN was lower than expected given the cytology reports, and correlation may improve with more provider experience. Further studies should evaluate the rate of anal cancer in HIV-infected women in sub-Saharan Africa. HPV vaccination programs and anal cancer screening should be considered.

BACKGROUND

In Western countries, cancer currently accounts for approximately one-third of all causes of death in HIV-infected individuals. An increased risk of cancer has been found among HIV-infected individuals classified as non-AIDS defining malignancies (e.g. hepatocellular carcinoma, ano-genital cancers other than cervical cancer) and it is noteworthy that these malignancies are often related to persistent viral co-infections with hepatitis B or human papillomavirus. The highest incidence of non-AIDS defining malignancies was reported for anal cancer. Although most HIV-infected individuals live in Sub-Saharan Africa, the only available data on ano-genital dysplasia relates to cervical dysplasia and in general, there is limited data available on anal dysplasia in this population. ART use has shown little effect on cervical and anal dysplasia and a high prevalence of persistent infections with oncogenic HPV types despite ART use.

METHODS

Study Design: HIV-infected women from the ages 25-65 years were randomly recruited from Themba Lethu Clinic , the HIV unit at Helen Joseph Hospital, Johannesburg, South Africa. Women were educated regarding the screening study , signed consent and completed a questionnaire. The study was approved by the University of Witwatersrand ethics board and the University of North Carolina IRB. Each woman was her own internal control and had HPV testing per Digene HC2, standard cytology Pap smear followed by an anal swab sample fixed on a glass slide and anal HPV testing (Digene HC2). High Resonance Anoscopy (HRA) was done on all participants with abnormal anal cytology with anoscopic biopsy of visible lesions. To adjust for verification bias, 20% of women with negative anal cytology had HRA biopsy done for verification of the negative cytological results.

QA: Cytology was reported using the Bethesda system. Anoscopy results were used as the gold standard. Each HRA was recorded by digital photography and reviewed quarterly by the study team for accuracy of interpretation.

Statistics: Baseline characteristics of this cohort and the prevalence of anal dysplasia and different grades of dysplasia were summarized using descriptive statistics. HRA results were compared to those of anal cytology and anal HPV, as well as anal cytology and HPV to cervical cytology and HPV.

RESULTS

Table 1: Cervical HPV versus Cervical Cytology

	Cervical Cytology				
Cervical HPV	NEGATIVE	ASCUS	LSIL	HSIL	TOTAL
Negative	11 (12.5%)	1 (1.1%)	41 (46.6%)	2 (2.3%)	55 (62.5%)
Positive	3 (3.4%)	0 (0%)	13 (14.8%)	16 (18.2%)	32 (36.6%)
Unknown	0 (0%)	0 (0%)	1 (1.1%)	0 (0%)	1 (1.1%)
Total	14 (15.9%)	1 (1.1%)	55 (62.5%)	18 (20.5%)	88 (100%)

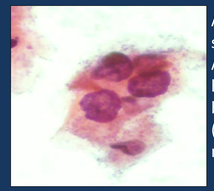

Anal smear showing high grade squamous intraepithelial lesion (HSIL). A small cluster of cells is noted with a high NC ratio, irregular nuclear borders and hyperchromasia. (Papanicolaou stain, high magnification)

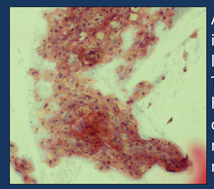

Anal smear showing low grade squamous intraepithelial lesion (LSIL). Loose c lusters of squamous cells are observed. The cells show evidence of a perinuclear halo, peripheral condensation of cytoplasm and enlarged, hyperchromatic nuclei (Papanicolaou stain, medium magnification).

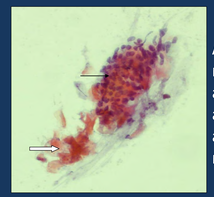

Anal smear showing some normal constituents including anucleate squamous cells (large arrow) and glandular cells (small arrow). (Papanicolaou stain, medium magnification).

Table 2: Anal HPV versus Anal Cytology

	Anal Cytology				
Anal HPV	Negative	ASCUS	LSIL	ASC-H/HSIL	TOTAL
Negative	6 (6.8%)	1(1.1%)	39 (44.3%)	4 (4.6%)	50 (56.8%)
Positive	3 (3.4%)	1 (1.1%)	21 (23.9%)	12 (13.6%)	37 (42.1%)
Unknown	0 (0%)	0 (0%)	1 (1.1%)	0 (0%)	1 (1.1%)
Total	9 (10.2%)	2 (2.3%)	61 (69.3%)	16 (18.2%)	88 (100%)

Table 4: HPV Positivity and HSIL by CD4 count

	CD4			
	<350 n=25	350-500 n=32	>500 n=31	Total n=88
HPV Positive	13 (52%)	14 (44%)	10 (32%)	37 (42%)
ASC-H/HSIL	7 (28%)	6 (19%)	3 (10%)	16 (18%)

Table 5: HPV Positivity and HSIL by year on ART

	Years on Art				
	No Art n=6	<3 Years n=31	3-5 Years n=30	>5 Years n=21	Total n=88
HPV Positive	5 (83%)	17 (55%)	9 (30%)	6 (29%)	37 (42%)
ASC-H/HSIL	1 (17%)	6 (19%)	6 (20%)	3 (14%)	16 (18%)

Table 3: Anal Biopsy versus Anal Cytology

	HRA Biopsy Diagnosis				
Anal Cytology	NILM	No Biopsy obtained#	Atypia/LGAIN	HGAIN	Total
Negative	1 (1.1%)	7 (7.8%)	1 (1.1%)	0 (0%)	9 (10.2%)
LSIL	25 (28.4%)	13 (14.8%)	18 (20.5%)	5 (5.7%)	61 (69.3%)
ASCUS	1 (1.1%)	0 (1.00%)	1 (1.1%)	0 (0%)	2 (2.7%)
ASC-H/HSIL	0 (0%)	2 (2.28%)	10 (11.4%)	4 (4.6%)	16 (18.2%)
Total	27 (30.7%)	22 (25.0%)	30 (34.1%)	9 (10%)	88 (100%)

#includes 9 participants who did not have HRA (7 per protocol and 2 LTFU) and 13 did not have lesions or biopsies were inadequate

High resolution anoscopy showing squamocolumnar junction after application of acetic acid

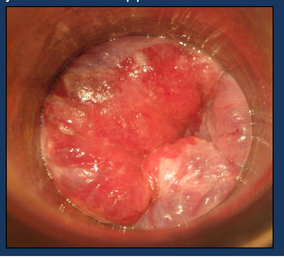

CONCLUSIONS

1. **We found a high prevalence of anal infection with high risk HPV (42%) and abnormal anal cytology (72% ASCUS/LSIL, 18% HSIL) in HIV-infected women. These rates are higher than those observed in the cervix.**
2. **Higher CD4 counts and longer time on ART appeared to be associated with lower rates of high risk HPV. Higher CD4 counts were associated with lower HSIL/ASC-H cytology.**
3. **HGAIN was found on HRA in 10%. This is likely an underestimate given the observed HSIL/ASC-H cytology.**

#