

# CCR5-Δ32 SCT HIV REMISSION – TRACES OF HIV DNA BUT FADING IMMUNOREACTIVITY

Björn-Erik O. Jensen<sup>1</sup>, Dieter Häussinger<sup>1</sup>, Elena Knops<sup>3</sup>, Annemarie Wensing<sup>5</sup>, Javier Martinez-Picado<sup>6</sup>, Monique Nijhuis<sup>5</sup>, Maria Salgado<sup>6</sup>, Jacob D. Estes<sup>10</sup>, Nadine Lübke<sup>4</sup>, Rolf Kaiser<sup>3</sup>, Thomas Harrer<sup>7</sup>, Johannes Fischer<sup>11</sup>, Johanna M. Eberhard<sup>8</sup>, Julian Schulze zur Wiesch<sup>8</sup>, Rainer Haas<sup>2</sup>, Guido Kobbe<sup>2</sup>

<sup>1</sup> Department of Gastroenterology, Hepatology and Infectious Diseases, University of Düsseldorf, Germany; <sup>2</sup> Department of Hematology, Oncology and Clinical Immunology, University of Düsseldorf, Germany; <sup>3</sup> Institute of Virology, University of Cologne, Germany; <sup>4</sup> Institute for Virology, University of Düsseldorf, Germany; <sup>5</sup> University Medical Center Utrecht, Netherlands; <sup>6</sup> IrsiCaixa Institute for AIDS Research, Badalona, Spain; <sup>7</sup> Medicine 3, University Hospital Erlangen, Germany; <sup>8</sup> I. Medical Clinic and Polyclinic, Medical Center Hamburg-Eppendorf, Germany <sup>9</sup> Institute of Transplantation Diagnostics and Cell Therapeutics, University of Düsseldorf, Germany <sup>10</sup> Division of Pathobiology and Immunology, Oregon National Primate Research Center, Oregon Health & Science University, USA

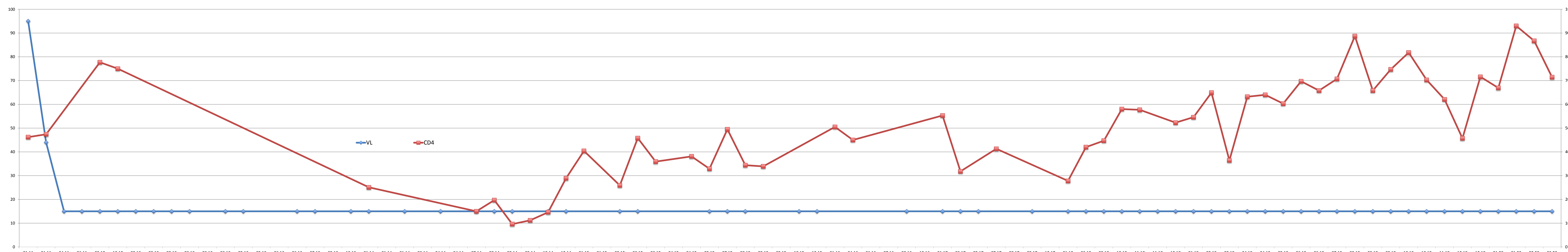
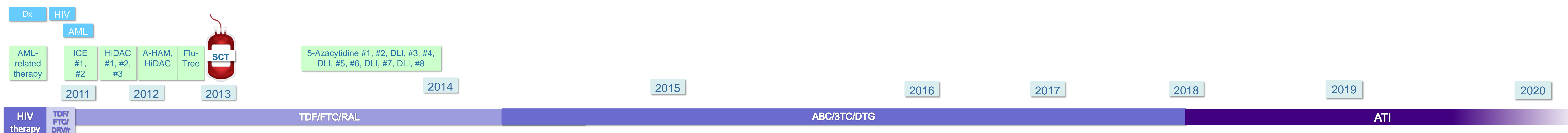
## BACKGROUND

- To date only 3 patients have achieved long-term HIV-remission after analytic therapy interruption (ATI).
- Here we provide an update of the Duesseldorf patient (IciStem#19).
- This HIV-infected male patient (50y, heterozygous CCR5Δ32 allele) received unmodified stem-cell transplantation (SCT) from a 10/10 matched CCR5Δ32/Δ32 donor in Feb/13 for acute myeloid leukemia.
- At time of SCT complete western blot pattern was detected, proviral load was 1.45 log<sub>10</sub>cop/Mio PBMCs with R5-coreceptor-tropism.
- In Jun/13 complete remission was achieved by 5-Azacytidine and donor lymphocyte infusions (DLI) after a 2nd relapse. PBMC were negative for HIV-DNA by qPCR/ddPCR during relapse and thereafter.
- However, in T-cell subsets few positive signals were observed. qVOA/mVOA were negative. Biopsies: CSF Jul/14, rectum Apr/15+Mar/16, ileum Mar/16 and bone marrow Aug/15, and lymph nodes (LN) May/17 were HIV-DNA negative by PCR.
- In situ hybridization assays (RNAscope, DNAscope) detected few positive signals in LN.
- Moderate acute and mild chronic GvHD occurred after DLI but Tacrolimus could be finally stopped in Oct/17. He remained on ART with undetectable plasma VL until analytic therapy interruption (ATI) in Nov/18.

## METHODS

- PBMC/tissues analysed by ddPCR/qPCR and in situ hybridization.
- T-cell responses with peptide stimulation assays. qVOA analysed on CD4+T-cells.
- Drug level assessment by liquid chromatography mass spectrometry.
- Patient is registered to IciStem as patient #19.

## WESTERN BLOT



## RESULTS

- After ATI no antiretrovirals could be detected in multiple plasma samples.
- In Jul/19 no HIV DNA was detected in CD45+ cells extracted from biopsies (duodenum/ileum/rectum).
- GI-tract: Neutrophils and IFN-1 responses very low
- GI-tract: CD4 T cells were abundant within GI tract follicular aggregates
- GI-tract: RNAscope was negative, DNAscope showed few positive signals, but not clearly above the false detection rate
- In Nov/19, 12 mo after ATI, HIV DNA was negative in naive, central memory, transitional memory, and effector/effector memory CD4 T-cells. qVOA in total CD4 T cells was also negative.
- Peptide stimulation assays showed CCR5-negative HIV-specific CTL with loss of recognition of RTYV9-specific and decrease of Gag-specific CTL after stopping immunosuppression. The absence of HIV-antigen is confirmed by fading humoral reactivity.

## SUMMARY & CONCLUSION

- No viral rebound was observed for 15 months following ATI, 83 months after allogeneic CCR5Δ32 SCT.
- In depth analyses of the viral reservoir still showed traces of HIV DNA in LN and GI tract, not clearly representing infectious virus though, since all functional assays were negative.
- These results are compatible with sustained remission of HIV.

We are grateful to the patient for his participation and commitment.